ACTA MEDICA TRANSILVANICA December27(4):46-48
Online ISSN 2285-7079

DAMAGE CONTROL SURGERY, OVERVIEW AND CURRENT CONCEPTS

IOAN ADRIAN POPENȚIU[1] , DORU FLORIAN CORNEL MOGA[2], ALEXANDRU SABĂU[3], DAN SABĂU[4]

[1,2] Sibiu Military Hospital, [1,2,3,4] "Lucian Blaga" University, Sibiu, [3]Sibiu County Emergency Clinical Hospital

Keywords: *damage control surgery, overview, recommendations*

Abstract: *Damage control surgery represents an option in treating severely polytraumatized patients, who cannot undergo extensive definitive surgical treatment, due to severe metabolic imbalances and hemodynamic instability. Although the term concerned initially only the abdominal trauma, now it can be used in all aspects of major posttraumatic injuries. We present a short history and systematisation of this concept, with emphasis on aspects related to visceral surgery. The principles of care, indications, procedures and current recommendations are also discussed.*

INTRODUCTION

The term damage control surgery was adapted from an expression used in the naval armed forces and naval industry, where it means simple and fast measures used for keeping a badly damaged ship afloat until the definitive repair is possible. Translating this into medical terms it means that patients from polytrauma do not have resources to undergo major surgery. In order to save their lives, a set of fast maneuvers are performed, then the patient is resuscitated, being able to go through a later, more time consuming procedure that will definitively manage the lesions.

It is considered that the first time a damage control surgery was performed and presented as such was in 1983.(1) Nevertheless, Pringle advocated fast maneuvers (Packing) for bleeding control after liver injuries since 1908.(2)

Generally speaking, there are 4 stages in the damage control surgery (DCS)(3): the decision to perform the surgery, after initial evaluation, the intervention, general resuscitation within intensive care unit, and second-look/definitive operation. Some authors consider only three of them(4): short surgery, ICU resuscitation, and definitive surgical care.

A. **Selection of the patients** that are candidates for DCS is based on the extent of the trauma, the difficulty to achieve haemostasis and to promote gas exchanges, but also on some findings such as:

a. a.Base deficit >8 mEq/L or worsening base deficit (3)
b. pH < 7.2
c. Hypotension < 90 mm Hg systolic
d. Hypothermia < 34° C
e. e.PTT > 60 seconds
f. Operative "clinical" coagulopathy

Asensio et al. (5) defined some factors that should indicate the patient as a candidate for damage control laparotomy or damage control surgery, generally speaking

Another set of inclusion criteria was developed by Moore et al (6)

B. Principles of Damage Control Surgery

Damage control laparotomy consists in fast opening and packing of the abdomen, in order to evaluate the full extent of the lesions. All the procedures should not last more than 90 minutes, otherwise the whole concept of DCS is transcended.

After the assessment, there are three main goals to achieve: haemorrhage control, contamination control and temporary abdominal closure

Figure no. 1. Risk factors for damage control surgery (6) (6)

Revised Trauma Score ≤ 5
pH ≤ 7.2
Temperature ≤ 34°C
≥2000 mL Crystalloid or ≥2 Units Packed Red Blood Cells resuscitation in the Emergency Department
Multiple mass casualties
Multisystem trauma with major abdominal injury
Open pelvic fracture with major abdominal injury
Major abdominal injury with need to evaluate early possible extra-abdominal injury
Traumatic amputation of limb with major abdominal injury
Need for emergency department thoracotomy
Need for adjunctive use of angioembolization

Figure no. 2. Inclusion criteria for damage control surgery (6)

Inability to achieve hemostasis owing to recalcitrant coagulopathy
Inaccessible major venous injury (eg, retrohepatic vena cava, pelvic veins)
Time-consuming procedure in the patient with suboptimal response to resuscitation (eg, pancreaticoduodenectomy, complex vascular reconstruction)
Management of extra-abdominal life-threatening injury (eg, active pelvic hemorrhage necessitating angiography, torn thoracic aorta)
Reassessment of intra-abdominal contents (eg, compromised intestinal blood supply due to extensive mesenteric injuries)
Inability to reapproximate abdominal fascia due to splanchnic reperfusion-induced visceral oedema (eg, following protracted shock that requires massive fluid resuscitation)

Haemorrhage control can and will be initiated even in the pre-hospital environment, using techniques developed mainly in the military medicine: use of tourniquets, haemostatic topical agents. The righteous use of tourniquets proved to save

[1]Corresponding author: Ioan Adrian Popențiu, B-dul. Victoriei, Nr. 46, Sibiu, România, E-mail: adipopentiu@yahoo.com, Phone: +4026 211209
Article received on 06.09.2022 and accepted for publication on 20.12.2022

live and limb during recent conflicts in Iraq and Afghanistan.(7-10) Topical haemostatic agents (dry fibrin, zeolite, chitosan) are to be used in extensive superficial lacerations, with small and medium vessels damage.(11,12)

Intra-abdominal haemostasis is achieved in the OR by direct ligation, packing, removal of destroyed organs (spleen, kidney) (13), or a combination of the above.

Contamination control is obtained by fast closure of hollow organs, with the use of stapling, or isolation of open intestinal ends (stoma creation), drainage.(14-17)

In the end, a method of temporary and incomplete closure of the abdomen is chosen depending on the experience of the team and the logistics on site. This will avoid the onset of the abdominal compartment syndrome, providing in the same time easy and fast access for the definitive care intervention. Methods used for this are: negative pressure systems, towel clip, Bogota bag, skin closure etc.(18,19)

C. ICU resuscitation

Figure no. 3. The vicious circle (20)

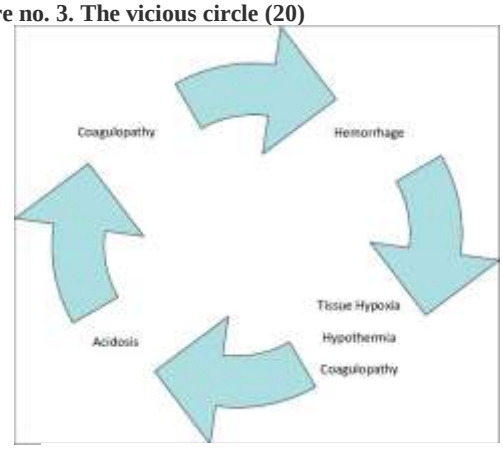

The lethal triade: hypothermia, acidosis and coagulopathy, is proven to worsen the prognosis for patient with polytrauma, if they are not addressed quickly.(20)

Damage control resuscitation begins in the prehospital phase of are or emergency department phase and should be continued throughout all stages of treatment.

Hypothermia is treated by isolating the patient during initial assessment and transportation, administration of warm IV fluids, the use of warming devices (hot air, electric blankets) and by maintaining the high temperature in the OR, ICU and ward.

The identification of patients with coagulopathy is an important aspect of damage control resuscitation. Damage control resuscitation consists of permissive hypotension; avoidance of excessive crystalloid, hypothermia, and acidosis; rapid surgical correction of anatomic hemorrhage, and early transfusion.(21)

Acidosis is a consequence of severe and prolonged tissue hypo-perfusion and subsequent switch from aerobic to anaerobic metabolism. In addition to that, impairment of oxygen utilization and the coagulopathy are associated with the acidotic state.(22-24)

D. Definitive surgical care

Ideally after 24-36 hours or more, if the resuscitation is unsuccessful, the patient is taken again in the OR. If necessary, a series of re-interventions will follow, especially if more complex maneuvers and multi-disciplinary teams are needed (plastic, orthopedic surgeon, urologist, etc.)

First step will be the removal of previously placed packs, and achievement of definitive hemostasis. If necessary, the packs can also be changed every 2-3 days.

Another vital step is the secondary survey of the abdomen, because sometimes one might find missed injuries from the first emergency laparotomy. If possible, the gastrointestinal continuity is restored, or if not possible, the definitive ostomy is created.

The more technical and time consuming vascular interventions are to be performed now (grafts, by-passes) , or permanent hemostasis.

If possible, another goal of definitive surgery is the closure of the abdominal wall. Due to the visceral edema, and/or abdominal wall injuries and contamination, this is not always possible. In order to manage this and to achieve a delayed or staged abdominal wall closure, several techniques and devices, such as negative pressure therapy devices, Bogota bag, Wittman patch, Fasciotens, etc. are used, depending on the team experience and the availability .

The transition from long surgeries aiming to restore the functional anatomy to abbreviated interventions with the only purpose to minimise the damage resulted in decreased morbidity and mortality among the selected patients (1,4) from the beginning of the concept application.

More recent studies underline the increase in survivability for damage control surgery after laparotomies.(25,26)

Damage control laparotomies are often followed by complications, such as intra-abdominal abscesses (0%–83%), enteric fistula (2%–25%), abdominal compartment syndrome (2%–25%), and failure to reapproximate the fascia edges (10–40%).(1,4,6,27,28)

CONCLUSIONS

Damage control surgery is a concept that is over 100 years old, and consists in abbreviated interventions, aiming only to limit the blood loss and the contamination, followed by a resuscitation interval in the ICU, and the later, curative intervention(s).

The biggest experience in refining this concept comes from the military environment, where this cases and situations are most often seen.

The damage control surgery is only a part from a more complex algorithm. One can divide the continuum of care into pre-surgery rapid transport and triage, damage control surgery, perioperative resuscitation, definitive repair of injuries temporized during damage control surgery, and delayed abdominal/chest closure and/or coverage of soft tissue wounds.

Although this is applied mostly for abdominal trauma, same principles are effective in treating selected patients with multi-visceral trauma or other anatomical segments (thorax, head, limbs, major vascular lesions)

Based on the good results obtained, damage control principles are starting to be used in non-trauma cases, such as abdominal compartment syndrome, or intra-abdominal sepsis (29,30).

REFERENCES

1. Stone HH, Strom PR, Mullins RJ, Management of the major coagulopathy with onset during laparotomy. Ann Surg. 1983 May;197(5):532-5. PMID 6847272
2. Pringle JH. Notes on the arrest of hepatic hemorrhage due to trauma. Ann Surg. 1908;48:541–9.
3. Craig Olson MD, Alexander L. Eastman MD, in Parkland Trauma Handbook (Third Edition) Chap 14; 2009. 93-96
4. Rotondo MF, Schwab CW, McGonigal MD, Phillips GR, 3rd, Fruchterman TM, Kauder DR, et al. 'Damage control': An approach for improved survival in exsanguinating penetrating abdominal injury. J Trauma. 1993;35:375–82.
5. Asensio JA, McDuffie L, Petrone P, Roldań G, Forno W,

Gambaro E, et al. Reliable variables in the exsanguinated patient which indicate damage control and predict outcome. Am J Surg. 2001;182:743–51.
6. Moore EE, Burch JM, Franciose RJ, Offner PJ, Biffl WL. Staged physiologic restoration and damage control surgery. World J Surg. 1998;22:1184–90.
7. Kragh JF, Jr, Littrel ML, Jones JA, Walters TJ, Baer DG, Wade CE, et al. Battle Casualty Survival with Emergency Tourniquet Use to Stop Limb Bleeding 2009. J Emerg Med. 2009
8. Kragh JF, Jr, Walters TJ, Baer DG, Fox CJ, Wade CE, Salinas J, et al. Practical use of emergency tourniquets to stop bleeding in major limb trauma. J Trauma. 2008;64:S38–49.
9. Kragh JF, Jr, Walters TJ, Baer DG, Fox CJ, Wade CE, Salinas J, et al. Survival with emergency tourniquet use to stop bleeding in major limb trauma. Ann Surg. 2009;249:1–7.
10. Lakstein D, Blumenfeld A, Sokolov T, Lin G, Bssorai R, Lynn M, et al. Tourniquets for hemorrhage control on the battlefield: A 4-year accumulated experience. J Trauma. 2003; 54:S221–5.
11. Achneck HE, Sileshi B, Jamiolkowski RM, Albala DM, Shapiro ML, Lawson JH. A comprehensive review of topical hemostatic agents: Efficacy and recommendations for use. Ann Surg. 2010;251:217–28
12. Cox ED, Schreiber MA, McManus J, Wade CE, Holcomb JB. New hemostatic agents in the combat setting. Transfusion. 2009;49:248S–55S.
13. Loveland JA, Boffard KD. Damage control in the abdomen and beyond. Br J Surg. 2004;91:1095–101.
14. Burch JM, Ortiz VB, Richardson RJ, Martin RR, Mattox KL, Jordan GL., Jr Abbreviated laparotomy and planned reoperation for critically injured patients. Ann Surg. 1992;215:476–83.
15. Carrillo EH, Bergamini TM, Miller FB, Richardson JD. Abdominal vascular injuries. J Trauma. 1997;43:164–71.
16. Feliciano DV, Mattox KL, Burch JM, Bitondo CG, Jordan GL., Jr Packing for control of hepatic hemorrhage. J Trauma. 1986;26:738–43.
17. Reilly PM, Rotondo MF, Carpenter JP, Sherr SA, Schwab CW. Temporary vascular continuity during damage control: Intraluminal shunting for proximal superior mesenteric artery injury. J Trauma. 1995;39:757–60.
18. Barker DE, Green JM, Maxwell RA, Smith PW, Mejia VA, Dart BW, et al. Experience with vacuum-pack temporary abdominal wound closure in 258 trauma and general and vascular surgical patients. J Am Coll Surg. 2007;204:784–92. [P
19. Garner GB, Ware DN, Cocanour CS, Duke JH, McKinley BA, Kozar RA, et al. Vacuum-assisted wound closure provides early fascial reapproximation in trauma patients with open abdomens. Am J Surg. 2001;182:630–8.
20. Kashuk JL, Moore EE, Millikan JS, Moore JB. Major abdominal vascular trauma--a unified approach. J Trauma. 1982;22:672–9.
21. Chang R, Kerby JD, Kalkwarf KJ, Van Belle G, Fox EE, Cotton BA, Cohen MJ, Schreiber MA, Brasel K, Bulger EM, Inaba K, Rizoli S, Podbielski JM, Wade CE, Holcomb JB, PROPPR Study Group , Earlier time to hemostasis is associated with decreased mortality and rate of complications: Results from the Pragmatic Randomized Optimal Platelet and Plasma Ratio trial. J Trauma Acute Care Surg. 2019;87(2):342.
22. Dunn EL, Moore EE, Breslich DJ, Galloway WB. Acidosis-induced coagulopathy. Surg Forum. 1979;30:471–3.
23. Manger WM, Nahas GG, Hassam D, Habif DV, Papper EM. Effect of pH control and increased O2 delivery on the course of hemorrhagic shock. Ann Surg. 1962;156:503–10.
24. Moore EE, Dunn EL, Breslich DJ, Galloway WB. Platelet abnormalities associated with massive autotransfusion. J Trauma. 1980;20:1052–6.
25. Finlay IG, Edwards TJ, Lambert AW. Damage control laparotomy. Br J Surg. 2004;91:83–5.
26. Nicholas JM, Rix EP, Easley KA, Feliciano DV, Cava RA, Ingram WL, et al. Changing patterns in the management of penetrating abdominal trauma: The more things change, the more they stay the same. J Trauma. 2003;55:1095–108.
27. Hirshberg A, Wall MJ, Jr, Mattox KL. Planned reoperation for trauma: A two year experience with 124 consecutive patients. J Trauma. 1994;37:365–9.
28. Ekeh AP, McCarthy MC, Woods RJ, Walusimbi M, Saxe JM, Patterson LA. Delayed closure of ventral abdominal hernias after severe trauma. Am J Surg. 2006;191:391–5.
29. Stawicki SP, Brooks A, Bilski T, Scaff D, Gupta R, Schwab CW, et al. The concept of damage control: Extending the paradigm to emergency general surgery. Injury. 2008;39:93–101.
30. Van Ruler O, Mahler CW, Boer KR, Reuland EA, Gooszen HG, Opmeer BC, et al. Comparison of on-demand vs planned relaparotomy strategy in patients with severe peritonitis: A randomized trial. JAMA. 2007;298:865–72.