

# SPONTANEOUS MESENTERIC HEMATOMA BY JEJUNAL ARTERY RUPTURE, COMPLICATION OF ORAL ANTICOAGULANT THERAPY, A CASE REPORT AND LITERATURE REVIEW

BOGDAN ANDREI SUCIU<sup>1</sup>, IOANA HĂLMACIU<sup>2</sup>, VASILE BUD<sup>3</sup>, CONSTANTIN COPOTOIU<sup>4</sup>, CĂLIN MOLNAR<sup>5</sup>, KLARA BRÎNZANIUC<sup>6</sup>

<sup>1,3,4,5</sup> 1<sup>st</sup> Surgical Clinic, University County Hospital Tîrgu-Mureş, <sup>1,2,3,4,5,6</sup> University of Medicine and Pharmacy Tîrgu-Mureş

**Keywords:** spontaneous mesenteric hematoma, jejunal artery, anticoagulant therapy

**Abstract:** Mesenteric hematoma is a rare clinical condition often associated with abdominal trauma. Non-traumatic mesenteric hematoma is a very rare condition, literature describing less than 100 cases often associated with acute pancreatitis, visceral artery aneurysm rupture, systemic inflammatory disease, and a complication of long term oral anticoagulant treatment. We present the case of a 46-year old Caucasian man that was admitted to the acute surgical admission unit at the County University Hospital Tîrgu-Mureş, România, for sudden-onset upper quadrant abdominal pain. No history of abdominal trauma or systemic inflammatory disease was noted. A subsequent therapy with Trombostop (warfarine, oral anticoagulant therapy) was prescribed one year ago, for a cardiovascular disease. On admission, the patient had clinical signs of hemorrhagic shock. Subsequent contrast abdominal computer tomography scans reveal a well-defined ovoid mass in close relation to the small bowel tract measuring 12x 5.2x 3.3 cm, and leak of contrast substance at the lower pole. The leak source was unclear but highly suggestive for an emerging mesenteric trunk artery, possible one of the jejunal arteries. Median laparotomy was performed and a large mesenteric hematoma caused by jejunal artery rupture was found and a large volume of blood was removed from the peritoneal cavity (more than 2000 milliliters). Jejunal resection was performed along with lateral jejunal anastomosis. Our case demonstrates that the risk of bleeding in a patient taking anticoagulant treatment exist even if treatment is properly administered.

## INTRODUCTION

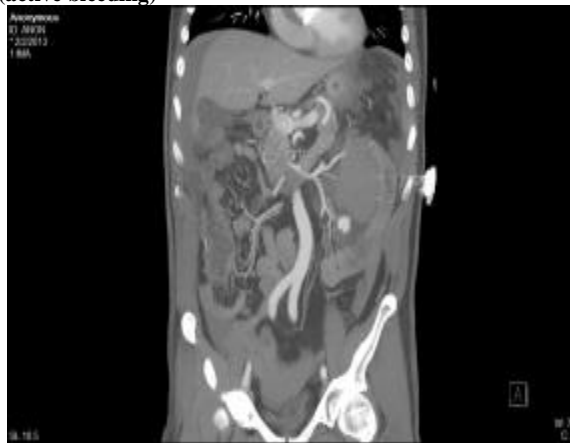
Mesenteric hematoma is a rare clinical condition often associated with abdominal trauma.(1) Non-traumatic mesenteric hematoma is a very rare condition, literature describing less than 100 cases often associated with acute pancreatitis (2), visceral artery aneurysm rupture (3), systemic inflammatory disease (4), and a complication of long term oral anticoagulant treatment.(5) Often, mesenteric hematoma opens in peritoneal cavity and leads to hemorrhagic shock (6) or can also exhibit extrinsic compression of the gastrointestinal tract leading to partial or complete obstruction.(7)

## CASE REPORT

A 46-year old Caucasian man was admitted to the acute surgical admission unit at the County University Hospital Tîrgu-Mureş, România, for sudden-onset upper quadrant abdominal pain. No history of abdominal trauma or systemic inflammatory disease was noted. One year ago, he underwent a surgical replacement of aortic trunk, valve and coronaries arteries reimplantation (Bentall procedure). A subsequent therapy with Trombostop (oral anticoagulant therapy) and Aspenter (antiplatelet therapy) was prescribed. Clinical examination revealed cold and pale skin, weak pulsation of peripheral arteries, low systemic blood pressure (70/40 mmHg), tachycardia (HR 125/minute), direct abdominal tenderness, abdominal distension and hyperesthesia; laboratory findings except for hemoglobin of 7.1 g/dl (normal 14-17 g/dl) and

hematocrit (28%) were all within normal range. The coagulation tests have shown no signs of dicumarinic overdose (INR was 1.98). Subsequent contrast abdominal computer tomography scans revealed a well-defined ovoid mass in close relation to the small bowel tract measuring 12x 5.2x 3.3 cm, and leak of contrast substance at the lower pole (figure no. 1).

**Figure no. 1. CT scan appearance of mesenteric hematoma, extravasation of the contrast substance in the jejunal artery (active bleeding)**



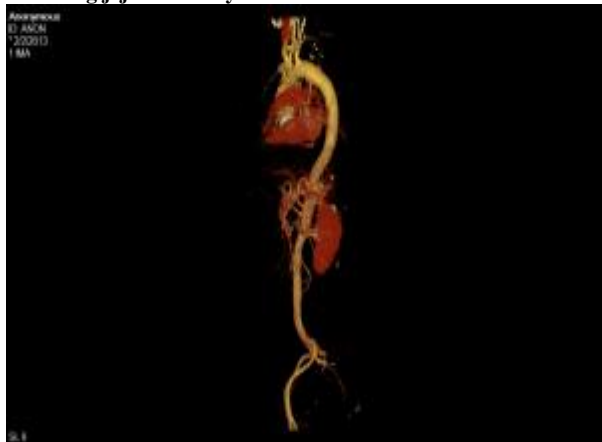<sup>2</sup>Corresponding author: Ioana Hălmăciu, Str. Gheorghe Marinescu, Nr. 38, Cod 540139, Tîrgu-Mureş, România, Email : anca\_halmăciu@yahoo.com, Phone: +40740 091324

Article received on 12.08.2015 and accepted for publication on 19.09.2016  
ACTA MEDICA TRANSILVANICA September 2016;21(3):73-75

## CLINICAL ASPECTS

The leak source was unclear but highly suggestive for an emerging mesenteric trunk artery, possible one of the jejunal arteries (figure no. 2).

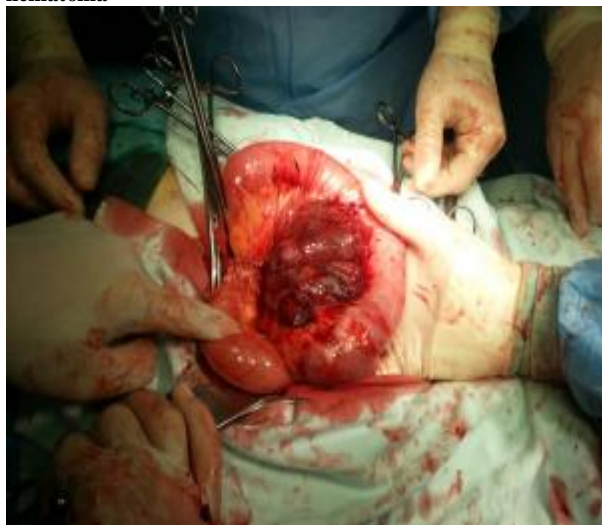**Figure no. 2. CT scan, 3D reconstruction, highlighting the offending jejunal artery and mesenteric hematoma**



CT scan also reveals the presence of the blood in peritoneal cavity. Venous phase of the leak source on the CT scan exploration demonstrated the same density as in aortic lumen that was highly suggestive sign of arterial source of leak. No other vascular malformation or pseudo cyst complicating acute pancreatitis was noted. At this particular moment, taking into consideration the unstable vital signs, the decision to undergo to emergency surgery was made. Median laparotomy was performed and a large mesenteric hematoma caused by jejunal artery rupture was found and a large volume of blood was removed from the peritoneal cavity (more than 2000 milliliters) (figure no. 3)

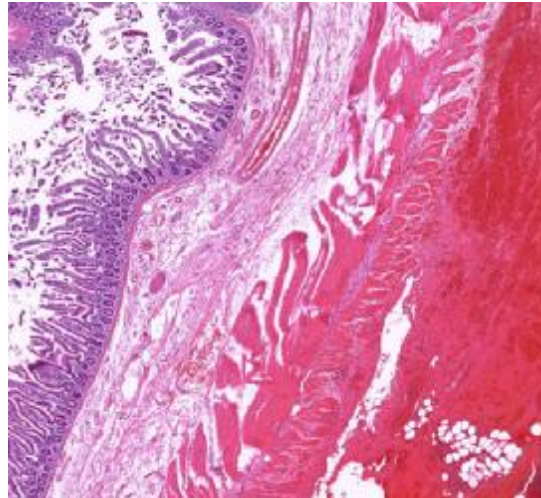
Jejunal resection was performed along with lateral jejunal anastomosis, peritoneal cavity was washed, and an intra-peritoneally drain tube was placed for the removal of any residual fluids. The recovery after the surgical treatment was uneventful and after 10 days the patient was discharged.

**Figure no. 3. The intraoperative aspect of the mesenteric hematoma**



The histologic examination of the resected segment of jejunum demonstrated the existence of a massive hematoma in the intestinal wall (figure no. 4).

**Figure no. 4. Hematoxyline-Eozine, Ob 2x, Giant hematoma into the intestinal wall**



## DISCUSSIONS

Spontaneous mesenteric hematoma is a very rare condition. Clinical signs range widely according to size and importance of the damaged vessels, and also the amount of blood leak and location of the rupture. If rupture involves small vessels, the amount of blood in peritoneal cavity is insignificant and the condition could be asymptomatic.(8,9) Other authors describe conservative treatment for those patients who are asymptomatic or with minor signs like vomiting or non-specific abdominal pain in the absence of obvious underlying pathology.(10) For those patients with signs of hemorrhagic shock, like our patient, the surgical treatment is mandatory after appropriate laboratory and radiological investigation. In the absence of an obvious underlying condition like pancreatitis, peptic ulcer disease, or trauma, urgent CT scan examination of the abdomen is an ideal first line investigation. In cases where an arterial aneurysm is suspected, an angiography is indicated.(3) Hence, in cases where CT scan findings are indeterminate and the threatening of life signs were present, like in our case, a contrast MRI of the abdomen or angiography or gallium scintigraphy, like others authors suggest (2), could only delayed the optimum time of surgical treatment.

Like other authors report, our patient presents symptoms of intestinal obstruction due to extrinsic pressure effect of the mesenteric hematoma on the bowel, ischemia of the bowel or associated intramural bowel hematoma.(11,12)

In the absence of pancreatitis, abdominal trauma or peptic disease, urgent CT examination of the abdomen is optimal first-line investigation; a contrast CT scan permit clinicians to exclude differential diagnosis such as acute pancreatitis.(13)

Hemorrhage is the most common complication of anticoagulant therapy. It is imperative that patients considered for long term anticoagulant therapy be selected carefully. For those patients followed regularly and with prothrombin determination in normal range, like our patient, timely intervention is essential to ensure a good outcome in this rare case of abdominal emergency.

Usually, the bleeding complications due to the anticoagulation therapy arise from overdosing. In the literature, there are cited cases of spontaneous non-traumatic hematoma following anticoagulant treatment at patients with normal therapeutic INR values.(14-17) In the peritoneal cavity, the most common bleeding complications that occur due to the

## CLINICAL ASPECTS

anticoagulant therapy are the hematomas of the wall of the small bowel.(18,19)

In the medical literature, there has been cited a case of spontaneous hematoma localized to the ureter, but there has not been cited until now any case of a non-traumatic jejunal artery rupture that appears in a patient due to the warfarin therapy.(20)

With the increasing use of therapeutic anticoagulation, the general surgeon will be confronted with new problems in the care of patients with an induced bleeding tendency in which acute surgical conditions develop. A tentative approach to the management of these patients is presented in this report. Our case demonstrates that the risk of bleeding in a patient taking anticoagulant treatment exist even if treatment is properly administered.

### REFERENCES

1. Asayama Y, Matsumoto S, Isoda T, Kunitake N, Nakashima H. A case of traumatic mesenteric bleeding controlled by only transcatheter arterial embolization Cardiovasc Intervent Radiol. 2005 Mar-Apr; 28(2):256-8.
2. Takayuki T, Sakae N, Kennoki O, Morisuke N, Toshihiko S, Takahiro O, et al. Case of a bleeding pseudoaneurysm of the middle colic artery complicating acute pancreatitis. Hepatogastroenterology. 2002;49:1141-3.
3. Skudder PA, Jr, Craver WL. Mesenteric hematoma suggests rupture of visceral artery aneurysm. Arch Surg. 1984;119:863.
4. Chih-Cheng Lai, Chu-Hsin Chuang, Chien-Ming Chao, Wei-Lun Liu, Ching-Cheng Hou, Spontaneous Intramural Small-Bowel Hematoma: A Rare Complication of Anticoagulant Therapy in an Elderly Patient International Journal of Gerontology. 2012;6(3):229-230.
5. Becker A, Berlin Y, Sayfan J. Spontaneous rupture of mesenteric hematoma with hemorrhagic shock as a complication of oral anticoagulant treatment. Isr Med Assoc J. 1999;1:196-7.
6. Parker SG, Thompson JN. Spontaneous mesenteric haematoma; diagnosis and management, BMJ Case Reports; 2012; doi:10.1136/bcr-2012-006624.
7. Weinstock LB, Wu JS, Malden ES, Garcia KM, Rubin BG, Brunt LM. Small bowel obstruction resulting from mesenteric hematoma caused by spontaneous rupture of a jejunal branch artery. Gastrointest Endosc. 1999;49:537-40.
8. Rana KVS, Panchabhai SV, Srihari S, Kharde K. Spontaneous mesenteric hemorrhage, Med J DY Patil Univ. 2013;6:95-7.
9. Fon GT, Hunter TB, Haber K. Utility of ultrasound for the diagnosis of mesenteric hematoma, AJR AM J Roentgenol. 1980;134:381-4.
10. Gomez D, Rahman SH, Guillou PJ. Spontaneous mesenteric Hematoma: A diagnostic challenge. Ann R Coll Surg Engl. 2006 May;88(3):W1-W3.
11. Adelman MI, Gishen P, Dubbins P, Mibashan RS. Localised intramesenteric haemorrhage-a recognisable syndrome in haemophilia? Br Med J. 1979;2:642-3.
12. Askey JM. Small bowel obstruction due to intramural hematoma during anticoagulant therapy, a non-surgical condition. Calif Med. 1966;104:449-53.
13. Furlan A, Fakhran S, Federle MP. Spontaneous Abdominal Hemorrhage: Causes, CT findings, and clinical implications, American Journal of Roentgenology. 2009;193:1077-1087.
14. Folgado Alberto S, Sanchez P, Felix J y Joaõ Ramos Deusa. Hematoma intramural espontaneo no traumatico del intestino delgado: una complicacion poco habitual de los anticoagulantes, Gastroenterol Hepatol. 2009;32(5):346-348.
15. Polat C, Dervisoglu A, Guven H, Kaya E, Malazgirt Z, Danaci M, et al. Anticoagulant-induced intramural intestinal hematoma. Am J Emerg Med. 2003;21:208-11.
16. Gooldfarb WB. Coumadin-induced intestinal obstruction. Ann Surg. 1965;161:27.
17. Meyer C, Otteni F, Hollender LF. Intestinal occlusion due to an intramural hematoma. Chir Gastroenterol. 1972;6:64.
18. Lobo L, Koudki R, Prasad K, Shetty B. Colon obstruction due to an anticoagulant induced intramural haematoma, a rare case report, Journal of Clinical and Diagnostic Research. 2013 April;7(4):739-741.
19. Krysa J, Shahabdeen M, South LM. A case of acute large bowel obstruction, presenting in a patient taking warfarin. Emerg Med J. 2003;20:e8.
20. Velut G, Bagnères D, Portier F, Bagatini S, Demoux AL, Chaumoître K, France Y. Hématome de l'uretère compliquant un traitement par anticoagulant : à propos d'un cas et revue de la littérature, Rev Méd Interne. 2000;21:903-10.