SECONDARY OMENTAL TORSION – A PREOPERATIVE DIAGNOSTIC DILEMMA. CASE REPORT AND DATA FROM THE SPECIALIZED LITERATURE

DANIEL COCHIOR[1], DUMITRU TOMA[2], MIHAELA LUMINIȚA MUNTEANU[3], ZOLTAN KOVER[4], MIHAELA ANCA POPESCU[5], SILVIA VASILE[6], IURII MUNTEANU[7]

[1,4]"Titu Maiorescu" University, Bucharest, [2,3,4,6,7]The Clinical Hospital CF-2, Bucharest, [5]The Clinical Hospital of Infectious and Tropical Diseases "Prof. Dr. Victor Babeș", Bucharest, "Carol Davila" University of Medicine and Pharmacy, Bucharest

Keywords: *omental torsion, omental tumour, acute surgical abdomen*

Abstract: *Omental torsion is a rare surgical pathology. More frequently, it is associated with an acute surgical abdomen syndrome, making a preoperative diagnosis rarely possible. Since there are no pathognomonic signs, imaging techniques are not able to accurately establish the diagnosis. We present the case of a 45-year-old male patient who was hospitalized for what appeared to be a voluminous left inguinal hernia, concurrently accusing symptoms of dyspepsia, while the clinical exam revealed the presence of a tumour formation located on the left abdominal flank, extending towards the left inguinoscrotal area. Abdominal CT suggested an omental torsion, hypothesis that, despite of arousing controversy of interpretation, was confirmed intraoperatively. Surgical treatment was limited to omentectomy and repair of the hernia, with a favourable postoperative evolution.*

INTRODUCTION

Omental torsion is more frequently diagnosed among overweight middle-aged males and it represents a rare surgical condition responsible for acute abdominal pain, with less than 250 cases having been reported since Eitel first described it, in 1899.(1,2,3,4)

This pathology occurs when a pedicle of the organ is rotated around a proximal fixed point along its long axis, with one end of the omentum remaining free in cases without any associated intra-abdominal diseases (primary torsion), or fixed in cases with an underlying condition such as scarring, cysts, hernias, appendicitis, cholecystitis, tumours (secondary torsion), resulting in vascular impairment of the omentum.(1,2,3,5,6)

Its clinical expression consists of various nonspecific symptoms of which the most common is pain, usually localised in the right lower portion of the abdomen, thus leading to preoperative misdiagnosis – most often acute appendicitis, but also acute cholecystitis or diverticulitis.(2,4,7)

It has been reported that an accurate preoperative diagnosis has been established in only 0.6 to 4.8% of the cases, although many authors suggest that radiological imaging such as ultrasonography and especially computed tomography have significantly increased the accuracy of the paraclinical preoperative diagnosis, allowing a more conservative therapeutic attitude.(4,8,9,10)

Some authors reported that exploratory laparoscopy should be the preferred diagnosis and therapeutic choice, but many agree that despite the advantages of minimally invasive surgery, exploratory laparotomy remains the gold standard for this condition.(2,3,10)

PURPOSE

Our aim is to highlight particularities concerning the preoperative diagnosis and the therapeutic approach of omental torsion, through the use of observations drawn from both the presented case and also from specialized literature.

CASE REPORT

We present the case of a 45-year-old male patient of rural provenience, without any significant heredocollateral or personal background, who was admitted to the general surgery department for a voluminous pseudotumoral formation located on the left abdominal flank and extending towards the left inguinoscrotal area, that had been developing for a period of about five years during which its size increased and subsequently, it had become irreducible. The patient also presented with permanent symmetric abdominal distension associated with dyspepsia.

Objective physical examination revealed a slightly dehydrated patient and the presence of a painless, irreducible and relatively well defined pseudotumoral formation of about 15x20 cm, of firm consistency, adherent to the posterior plan, which was located in the left abdominal flank, extending towards the left inguinoscrotal region over an area of 10x15 cm, where the mass had a softer consistency.

In terms of paraclinical exams, laboratory tests were within normal values, as well as thoracic and abdominal radiographs, which revealed no pathological processes.

Abdominal ultrasound highlighted a complex solid mass with hypoechoic components, which was situated in the left abdominal flank directly under the posterior surface of the abdominal wall, with a direct connection with the contents of the left inguinoscrotal hernia. Color flow Doppler mode abdominal ultrasound revealed the same changes, suggesting continuity of the mass towards the left anterolateral side of the abdomen, at the same time identifying a rather well defined tumor vasculature.

The abdominopelvic CT exam identified a vascularised inhomogeneous oval fat-density mass of 15 x 20 x 7 cm, with irregular edges and streaks of whirling pattern, located in the left abdominal flank.

The fact that the mass presented with its own vasculature, which had not been completely compromised,

[7]Corresponding author: Iurii Munteanu, B-dul. Mărăști, Nr. 53, Sector 1, București, România, E-mail: iuriimunteanu@yahoo.co.uk, Phone: +4021 3162523
Article received on 09.08.2016 and accepted for publication on 19.09.2016
ACTA MEDICA TRANSILVANICA September 2016;21(3):66-68

suggested a possible malignant component, raising the suspicion of a retroperitoneal liposarcoma. Nevertheless, the left gastroepiploic vessels were captured in certain venous sequences on the CT and it could be observed that the contrast material penetrated the gastroepiploic vessels and subsequently, the abdominal mass, gradually reaching the left inguinoscrotal hernia content.

Figure no. 1. Abdominal-pelvic CT with contrast: omental torsion

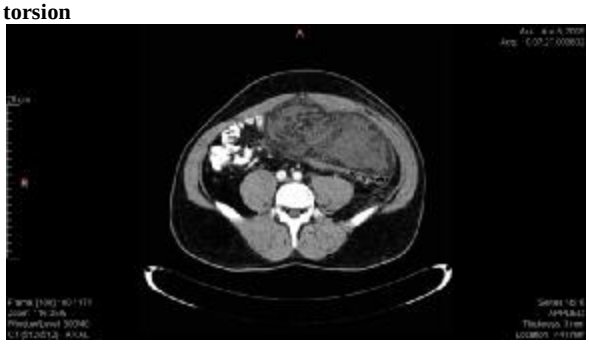

By following, the ultrasonographic aspect of the lesion, especially its direct connection with the hernia contents, associated with the presence of the "whirl sign" and the characteristics of the tumor's vasculare on the CT led to the conclusion that an omental torsion was far more likely.

Figure no. 2. A and B. Abdominal-pelvic CT with contrast, volume reconstruction: omental torsion with left inguinoscrotal hernia

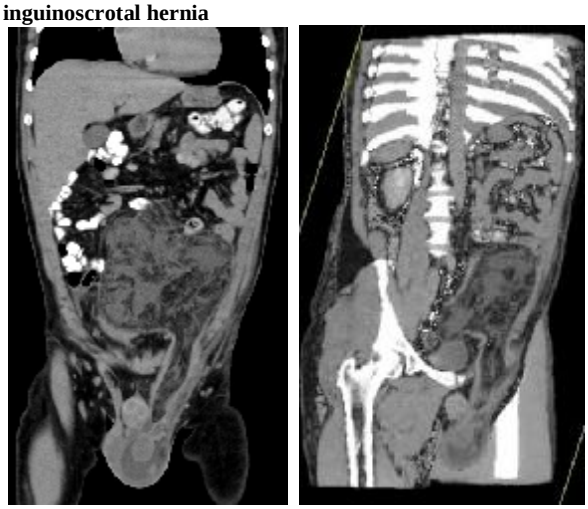

After hydroelectrolytic rebalancing and having prepared the digestive tract, surgery was performed, uncovering a 15x20 cm mass represented by a great omentum axial torsion that was tractioned towards the left paracolic recess and herniated, in its distal portion, through the deep inguinal ring, resulting in the content of the incarcerated left inguinoscrotal hernia which had been diagnosed preoperatively.

Intraoperative appearance of the mass imposed an exhaustive inventory of the tumour's framework, with a firm diagnosis having been established only after complete viscerolysis, which individualized and restored the local anatomy that had been disrupted throughout the evolution of the omental torsion. The surgical procedure consisted of subtotal ablation of the greater omentum along with its twisted portion, associated with left inguinoscrotal hernia repair by the Lichtenstein technique.

Macroscopic appearance of the resected specimen indicated two points of rotation around which the torsion had occurred.

Figure no. 3. Omental torsion - intraoperative aspect

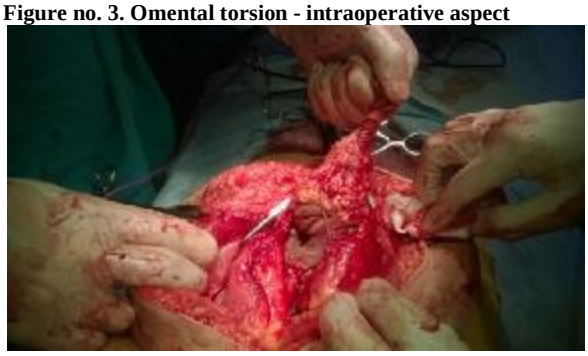

Figure no. 4. The resected specimen

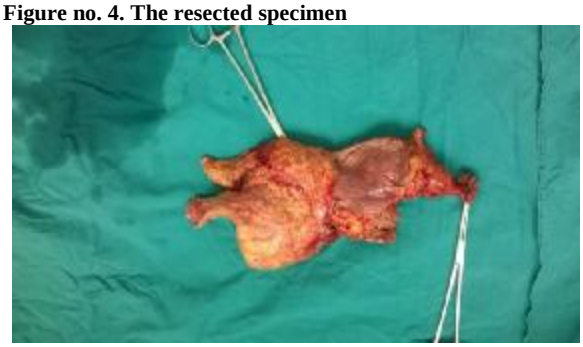

RESULTS

Postoperative evolution was favourable, with per primam postoperative healing, and the patient was discharged after 5 days, for outpatient observation.

The particularity of the case consisted of a chronic omental torsion with a pseudotumoral evolution and a minimally painful symptomatology, as well as the fact that local vascularisation was not completely compromised.

DISCUSSIONS

Omental torsion represents a rare surgical abdominal pathology with a difficultly established preoperative diagnosis. In about 90% of the cases, omental torsion has an acute onset that mimics an acute surgical abdomen. This particular condition is frequently confused with other acute surgical pathologies, especially with acute appendicitis or acute cholecystitis. Most commonly, the right side of the omentum is subjected to torsion due to anatomical particularities that favour this process, such as a higher volume and mobility, a poor vascularization and the lack of collaterals.(11,12)

Etiopathogeny of omental torsion has yet to be perfectly elucidated to the present day. Although the etiology differs in the two described types of omental torsion – primary and secondary, a common trigger has been frequently incriminated. Thus, the torsion may be produced by a sudden surge in pressure in the peritoneal cavity, such as in the cases of an effort to cough, hiccup, defecate or even handling vibrating tools.

The physiopathological mechanism consecutive to omental torsion begins with a venous congestion that leads to local inflammatory response, adhesion formation and ultimately, if the obstruction also involves the arterial vascular axis, to necrosis. Omental infarction determines a painful

symptomatology of an acute surgical abdomen with an emergency surgical indication. Sometimes, a spontaneous derotation of the omentum is possible, which explains unspecific adhesions occasionally discovered intraoperatively.(13,14)

Although no certain cause can be incriminated in the etiology of primary omental torsion, this pathology is associated with certain developmental abnormalities, such as accessory omentum, bifid omentum, redundant omentum, vascular malformations of the omental veins.(1,4) This condition occurs most commonly in relation to an unexpected physical effort, sudden movement or trauma, hiccup, alimentary abuse or hyperperistalsis.(1,2,3) Usually, the torsion is unipolar, with a single point of rotation.(1)

Secondary omental torsion is usually caused by an underlying pathology and can be divided into two variants: one with a single point of rotation – such as in cases of torsion determined by omental tumors, anatomical malformations or venous dilatations, and a second variant, with two points of rotation, which can happen in cases of torsion produced due to hernias, adhesions or intra-abdominal tumors.(14)

Complications of omental torsion include rupture with intraperitoneal haemorrhage, purulent peritonitis and peritoneal abscesses or more rarely, inflammatory reactions followed by peritoneal fibrosis.(15)

Since the greater omentum, through its physiological properties, is able to withstand conditions of inflammation and ischemia by developing an impressive collateral circulation, the acute onset is usually followed by a period of partial or total clinical improvement. At other times, torsion occurs slowly and progressively, evolving with a poorly represented symptomatology or even completely asymptomatic. In such cases, chronic vascular disturbances provide the conditions necessary for organ hypertrophy, which can even determine a pseudotumoral aspect, as in the case presented above.

Treatment is usually surgical, frequently in an emergency regime. Common surgical techniques are limited to resection of the twisted portion and, in case of a secondary torsion, the triggering pathology is addressed. Some authors suggest that laparoscopic surgery should be preferred due to the possibility of an accurate diagnosis with minimally invasive surgical techniques, thus sparing the patient from a more aggressive intervention followed by a longer recovery time.(16)

CONCLUSIONS

Omental torsion represents a rare surgical pathology. Most often, it is qualified as a surgical emergency, requiring surgical intervention. Preoperative diagnosis is established with difficulty even with the aid of modern imaging techniques. Occasionally, this condition can evolve in a subacute manner, determining a fibrous inflammatory reaction with a pseudotumoral development, frequently responsible for preoperative misdiagnosing. When faced with acute surgical abdomen symptomatology, one should always take into consideration an omental torsion as a differential diagnosis.

REFERENCES

1. Saber AA, LaRaja RD. Omental Torsion. 2007, updated 2015. http://emedicine.medscape.com/article/191817-overview. Accessed 12.09.2016.
2. Ghosh Y, Arora R. Omental Torsion. J Clin Diagn Res. 2014;8(6):NE01-NE02.
3. Breunung N, Strauss P. A Diagnostic Challenge: Primary Omental Torsion and Literature Review – A Case Report. World J Emerg Surg. 2009;4:40.
4. Occhionorelli S, Zese M, Cappellari L, Stano L, Vasquez G. Acute Abdomen due to Primary Omental Torsion and Infarction.Case Rep Surg. 2014;2014:208382.
5. Jain P, Chhabra S, Parikh K, Vaidya A. Omental Torsion. J Indian Assoc Pediatr Surg. 2008;13(4):151-2.
6. Chen CD, Chen XM, Wu SC. A Child with the Rare Diagnosis of Acute Appendicitis and Omental Torsion. HK J Paediatr. 2012;17:254-7.
7. Katagiri H, Honjo K, Nasu M, Fujisawa M, Kojima K. Omental Infarction due to Omental Torsion. Case Rep Surg. 2013;2013:373810.
8. Mohamed A, Mohamed Y, Harera I. Primary Torsion of the Omentum: An Intraoperative Surprise, Case Report. Int J Surg. 2010;26(2):7162.
9. Khattala K, Tenorkorang SS, Elmadi A, Rami M, Bouabdallah Y. Primary Omental Torsion in Children: Case Report. Pan Afr Med J. 2013;14:57.
10. Joshi S, Cuthbert GA, Kerwat R. Omental Torsion, A Rare Cause of Acute Abdomen. BMJ Case Rep. 2016. http://casereports.bmj.com/content/2016/bcr-2015-213118.full.pdf.
11. Lacaze L, Attignon I, Lauzanne P, Scotté M. Torsion du grand épiploon associée à une hernie inguinale gauche. J Radiole Diagn Interv. 2012;93(5):423-5.
12. Coulier B.64-row MDCT review of anatomic features and variations of the normal greater omentum. Surg Radiol Anat. 2009;31:489-500.
13. Tandon AA, Lim KS. Torsion of the greater omentum: A Rare preoperative diagnosis. Indian J Radiol Imag. 2010;20(4):294-6.
14. Audi P, Amonkar D, Correia M, Nagarsenkar P, Vaz O. Torsion of Lobular Capillary Hemangioma of Greater Omentum: A Rare Cause of Acute Abdomen. Med J DY Patil Univ. 2015;8:836-9.
15. Alexiou K, Ioannidis A, Drikos I, Sikalias N, Economou N. Torsion of the Greater Omentum: Two Case Reports. J Med Case Rep. 2015;9:160.
16. Miguel Perelló J, Aguayo Albasini JL, Soria Aledo V, Aguilar Jiménez J, Flores Pastor B, Candel Arenas MF. Omental Torsion: Imaging Techniques Can Prevent Unnecessary Surgical Interventions. Gastroenterol Hepatol. 2002;25(8):493-6.